



Atherton Hospital Endoscopy Unit
Cairns & Hinterland Health Service District
Jack Street
ATHERTON, QLD, 4882

Reception Phone: +61 7 4091 0211
Fax: +61 7 4091 0412

14/11/2022

JESS ADAMS, MD
MALANDA MEDICAL CARE
MALANDA QLD 4885

Re : Colonoscopy procedure for

Amanda Grech DOB:30/10/1990 U.R.N012864

Dear Dr. ADAMS

This procedure was performed on **Monday, 14 November 2022**. My impressions and recommendations are as follows:

Impressions:

- **The entire examined colon is normal.**
- **The examined portion of the ileum was normal.**
- **No specimens collected.**

Recommendations:

- **Discharge patient to home.**
- **Return to general practitioner.**

My findings are described in the full report, which is enclosed.

Thank you for referring this patient to me.

Sincerely,

Debra A. Whittaker, Nurse Practitioner/Nurse Endoscopist



Patient Name: Amanda Grech
UR Number: 012864
Admit Type: Outpatient
Gender: Female
Public/Private Patient: Public

Procedure Date: 14/11/2022 9:49 AM
Date of Birth: 30/10/1990
Age: 32
Room: Outpatient Theatre

Procedure Staff: Debra A. Whittaker, Nurse Practitioner/Nurse Endoscopist, Natasha Litchfield, Louis Peachey, MD

Referring Physician: JESS ADAMS, MD

Indications: Mucus passage PR

Procedure: Colonoscopy

Medicines: Monitored Anaesthesia Care

Procedure: After I obtained informed consent, the scope was passed under direct vision. Throughout the procedure, the patient's blood pressure, pulse, and oxygen saturations were monitored continuously. The Colonoscope was introduced through the anus and advanced to the terminal ileum. The colonoscopy was performed without difficulty. The patient tolerated the procedure well. The quality of the bowel preparation was evaluated using the Aronchick Scale with a colon score of 2 (Good: clear liquid covering up to 25 percent of mucosa, but more than 90 percent of mucosa seen).

Scope Withdrawal Time: 6 Minutes 8 Seconds

Total Procedure Duration Time: 17 Minutes

Complications: No immediate complications.

Findings:

- The perianal and digital rectal examinations were normal.
- The colon (entire examined portion) appeared normal.
- The retroflexed view of the distal rectum and anal verge was normal and showed no anal or rectal abnormalities.
- The terminal ileum appeared normal.

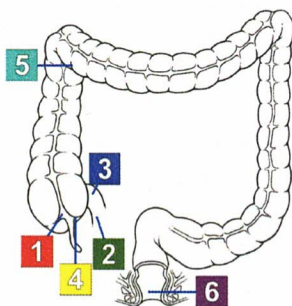
Impression:

- The entire examined colon is normal.
- The examined portion of the ileum was normal.
- No specimens collected.

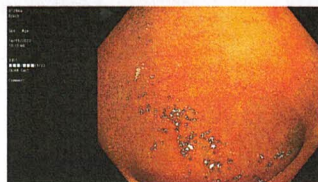
Recommendation:

- Discharge patient to home.
- Return to general practitioner.

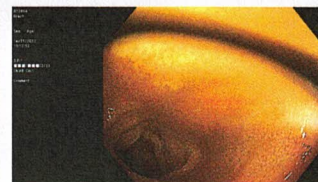Images:



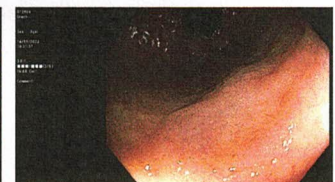The Colon



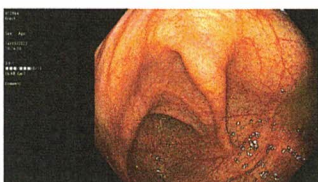
2 Terminal ileum : Normal
Terminal Ileum



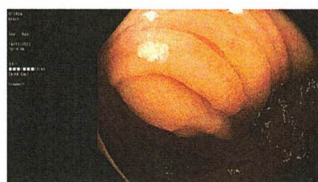3 Terminal ileum : Normal
Terminal Ileum



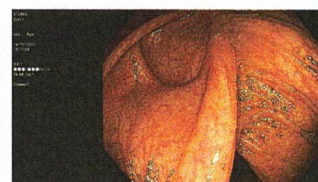6 Rectum :
Retroflexion/Normal
rectum



1 Caecum



4 Caecum



5 Hepatic Flexure



Patient Name:	Amanda Grech	Procedure Date:	14/11/2022 9:49 AM
UR Number:	012864	Date of Birth:	30/10/1990
Admit Type:	Outpatient	Age:	32
Gender:	Female	Room:	Outpatient Theatre
Public/Private Patient:	Public		

Debra A. Whittaker, Nurse Practitioner/Nurse
Endoscopist

Finalised Date: 14/11/2022 10:30:25 AM

This report has been signed electronically. Debra Whittaker, Nurse Practitioner/Nurse Endoscopist