

Colonoscopy

73666

Patient: Tahlia Crema
Gender: Female **Age:** 36
Referring: Dr Kapil Maharaj

Date: 15/05/2023 **Report N°:** 190672032
Equipment: FUJIFILM ENDOSCOPY

Indication:

chronic diarrhoea nad iron deficiency

Bowel Preparation Quality:

Good

Colonoscopy Result:

The colonoscope entered the terminal ileum and caecum.

There are no polyps, mucositis or cancers present.

Caecal and random colonic biopsies have been done.

Haemorrhoids are present in the rectum on scope retroflexion

Withdrawal 7 min

Followup:

1. Return to LMO
2. Review with Dr Froomes to check histology - Dorevitch

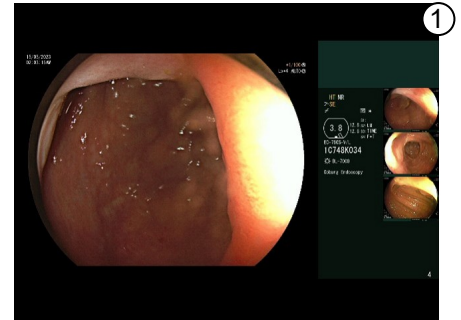
Conclusion and Treatment Recommendations:

NORMAL COLONOSCOPY

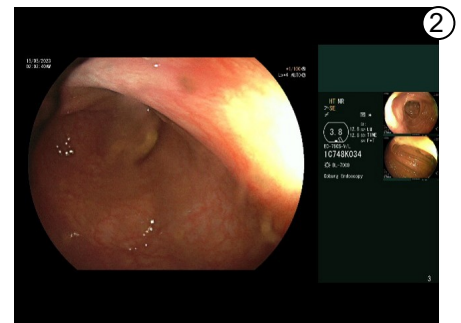
Codes:

32222

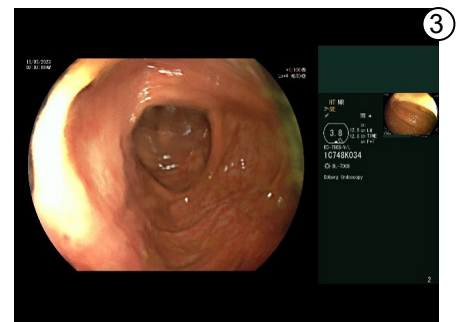
Dr Paul Froomes BMedS MBBS FRACP MD



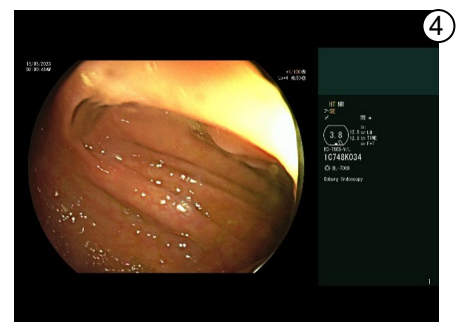
Rectum



Proximal sigmoid



Transverse colon



caecum