

Gastroscopy

73666

Patient: Tahlia Crema
Gender: Female **Age:** 36
Referring: Dr Kapil Maharaj

Date: 15/05/2023 **Report N°:** 190672031
Equipment: Olympus 190 series

Indication:

Iron deficiency

Oesophagus:

The esophagus was normal

The z line was located at 37cm from the mouth

Lower esophageal biopsies were taken

Gastric:

The stomach was normal

Antral biopsies were taken

Proximal Duodenum:

The duodenum is normal to D3 with 6 biopsies done of D1 and D2 to rule out coeliac - although no macroscopic signs of coeliac was seen today

Followup:

1. Return to LMO
2. Review with Dr Froomes to check histology - Dorevitch

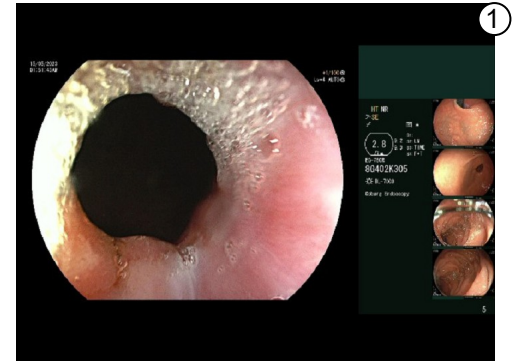
Conclusion and Treatment Recommendations:

NORMAL GASTROSCOPY

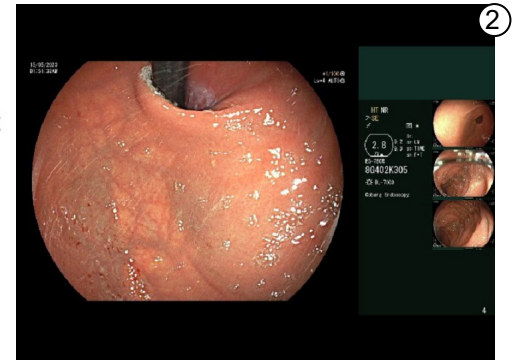
Codes:

30473

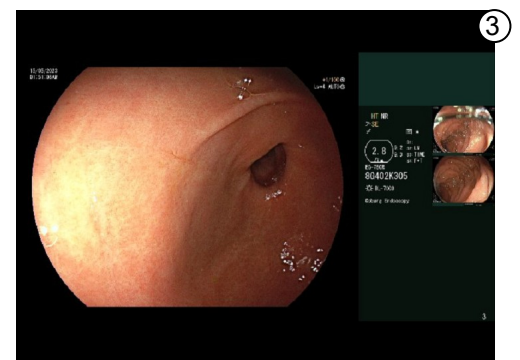
Dr Paul Froomes BMedS MBBS FRACP MD



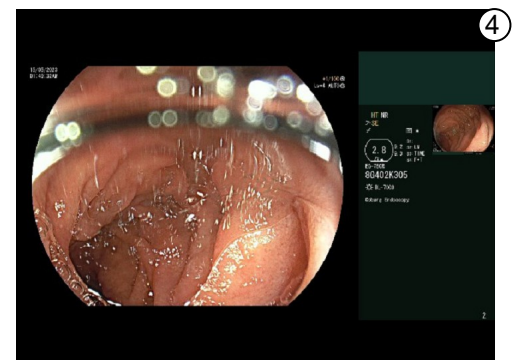
Lower oesophagus



Cardia



Gastric antrum



2nd part of duodenum