

**Government of South Australia**

SA Health

FMC-IP 6D Cardiac

Discharge Summary, Medical

MRN: FMC-600051885

Name: DENNARD, SCOTT EDWARD

DOB: 2/7/1994

Age: 28y

Sex: M

Address: 17 EDMONDS ROAD, SEAFORD HEIGHTS SA 5169

Admission Date: 24/01/2023 Discharge Date (actual): 27/01/2023 00:00

Location: FMC-6DC-17_20-18

DISCHARGE

Start of visit	24/01/2023
Expected Discharge Date	27-01-2023
Actual Discharge Date	27/01/2023

ALLERGIES/INTOLERANCES

ALLERGEN/PRODUCT	REACTION	ONSET
No Known Allergies		

SELECTED VISITS**Selected Visit**Admit Date
24/01/2023Discharge Date
27/01/2023Location
FMC-6DC-17_20-18**CARE PROVIDERS**

Joseph, Majo(Primary Consultant): Consultant, Cardiology

DISCHARGE DIAGNOSIS

Discharge Dx	3238004 - Pericarditis.
--------------	-------------------------

PROBLEMS**ED Diagnosis**

I308 - Other forms of acute pericarditis.

Visit Reason

I308 Other forms of acute pericarditis.

CLINICAL SYNOPSIS AND COMPLICATIONS**Clinical Synopsis**

**Government of South Australia**

SA Health

FMC-IP 6D Cardiac

MRN: FMC-600051885
Name: DENNARD, SCOTT EDWARD
DOB: 2/7/1994 Age: 28y Sex: M
Address: 17 EDMONDS ROAD, SEAFORD HEIGHTS SA 5169

Admission Date: 24/01/2023 Discharge Date (actual): 27/01/2023 00:00
Location: FMC-6DC-17_20-18

Discharge Summary, Medical**PROFILE:**

28yo male from home, independent with ADL's

GP:

Seaford Heights Medical Centre

Cardiologist:

nil.

PAST MEDICAL HISTORY:

GORD

Recurrent pericarditis

DIAGNOSIS:

Pericarditis

SUMMARY OF PRESENTATION:

Recurrent pericarditis

- 5th presentation for same

- 1st presentation to NHS ED July 22 - treated as pericarditis with ibuprofen

- 2nd time - patient reports nil presentation to GP/ED but self treated with ibuprofen

- 3rd time in Oct 22 - STEMI stood down, ECHO NAD

- 4th time FMC Jan 2023, repeat ECHO NAD

- on colchicine 500microg mane, ibuprofen 400mg TDS, pantoprazole 40mg mane

Medications

Nil change

INVESTIGATIONS:

Pathology: See attached pathology reports

FOLLOW UP

CARDIOLOGY FOLLOW UP REQUIRED - NO PRIOR CARDIOLOGIST: This patient has been referred to SA Heart for further cardiac care in regards to their Pericarditis. SA Hearts office will contact this patient to make arrangements for their review. We have suggested this patient also make their own arrangements to attend your practice to discuss their admission and any subsequent monitoring/follow-up required. Thank you for your ongoing care of this patient.

CT neck and chest booked for 9/2/23 at 1600hrs at FMC Radiology - results to be followed up in registrar clinic as case note review.

Patient referred to rheumatology OPD.

Thank you for your ongoing care.

DISCHARGE MEDICATIONS

MEDICATION DETAILS	SUPPLY ON DISCHARGE	DURATION/ STOP DATE
colchicine 500 microgram oral, TWICE a day	colchicine 500 microgram tablet Quantity: 30 Repeats: 1	Stop After: 7 Days
pantoprazole enteric coated tablet 40 mg oral, every morning	pantoprazole 40 mg enteric tablet Quantity: 30 Repeats: 0	

**Government of South Australia**

SA Health

FMC-IP 6D Cardiac

Discharge Summary, Medical

MRN: FMC-600051885
Name: DENNARD, SCOTT EDWARD
DOB: 2/7/1994 Age: 28y Sex: M
Address: 17 EDMONDS ROAD, SEAFORD HEIGHTS SA 5169

Admission Date: 24/01/2023 Discharge Date (actual): 27/01/2023 00:00
Location: FMC-6DC-17_20-18

prednisolone**Dose Taper/Titration - Start Date: 27-01-2023**

50 mg oral, every morning with food for 2 Days, then 25 mg oral, every morning with food for 5 Days, then 12.5 mg oral, every morning with food for 5 Days

prednisolone 25 mg tablet
Quantity: 30
Repeats: 0

Stop After:
08/02/2023

DISCHARGE DESTINATION

Actual Discharge Destination

Home - GP

MY HEALTH RECORD

My Health Record

Disclosed MHR found

FOLLOW-UP APPOINTMENTS**Follow-up appointment details**

No scheduled appointments found.

COPY TO**GP Details**

DR. PRACTICE RECORDS MANAGER
SEAFORD HEIGHTS MEDICAL CENTRE
SHOP 2 44 ROBINSON ROAD
SEAFORD HEIGHTS SA 5169

DOCUMENT DETAILS

Authored: 30/01/2023 11:54 by Flower, Ben (Medical Student)

Last updated: 01/02/2023 15:10 by Wattchow, Naomi (Medical Officer)

Author Signature: Flower, Ben

Flinders Medical Centre**Radiology Report****PATIENT DEMOGRAPHICS**

MRN : 600051885-FMC
NAME : DENNARD, SCOTT EDWARD
D.O.B. 02/07/1994 AGE : 28 y
GENDER: Male

SERVICE : XR Chest;
STATUS : Final
REQUESTED BY : PARKER, ALEXANDER
EXAMINED : 24/01/2023 17:48
REPORTED : 24/01/2023 18:49

PATIENT MRN: 600051885
PATIENT NAME: SCOTT EDWARD DENNARD
DATE OF BIRTH: 02/07/1994
STUDY DATE: 24/01/2023 STUDY TIME: 03:27 PM
REFERRING DR: PARKER, ALEXANDER, 5183331X, FMC
WARD UNIT: FMC-Emergency Department EMERGENCY CLINIC
EXAMINATION:
Study: XR Chest
Procedure(s): XRCHE - XR Chest
CLINICAL DETAILS:
recurrent pericarditis, presenting with bilateral chest pain
?heart failure ?pneumothorax
COMPARISON:
Chest x-ray: 03/01/2023
FINDINGS:
Normal cardiac and mediastinal contours. No features of pulmonary oedema. The
lungs and pleural reflections are clear.
REPORTED BY: Makenze Roberts, Registrar, 24/01/2023 06:49 PM

South Australia
Medical Imaging
Flinders Medical Centre

Medical Imaging
Flinders Medical Centre
Flinders Drive
Bedford Park SA 5042

Phone: Reception (08) 8204 4010
sahealth.sa.gov.au/sam1
ABN 96 269 526 412

MRN: 600051885 Visit: 111707167 Age: 28y (02-07-1994)	DENNARD, SCOTT EDWARD Gender: Male	Flinders Medical Centre Current Location: FMC-6DC-17_20-18
---	--	--

MEDical Progress Note-- Card (FMC) [Charted Location: FMC-6DC-17_20-18] [Date of Service: 27-Jan-2023 15:16, Authored: 27-Jan-2023 15:16]- for Visit: 111707167, Complete, Entered, Signed in Full, General

PROGRESS NOTE:
INTERVAL HISTORY:

• **Interval History**

thanks rheum

noted recommendations with thanks

will forward correspondence to GP for consideration of workup for weight lost
scripts given with plan for weaning pred and colchicine

please forward discharge summary to SA Heart for patient's appointment on 7th Feb
blood form given for repeat bloods prior to appointment if ongoing symptoms

discharge home today

Electronic Signatures:

Xiong, Libo (Medical Officer) (Signed 27-Jan-2023 15:18)

Authored: PROGRESS NOTE

Last Updated: 27-Jan-2023 15:18 by Xiong, Libo (Medical Officer)

Patient: DENNARD, Scott Edward MRN: FMC-600051885, DOB: 02 Jul 1994 Page 1 of 2

600051885 DENNARD, SCOTT EDWARD
DOB: 2-Jul-1994 28 years Male

Paced

26-Jan-2023 8:04:42

Page 1 of 1

RR 55
RR 1092
PR 159
QRS 95
QT 412
QTc 394

P-Axis -60
QRS 81
T 68

12 Lead ECG Report (Standard)

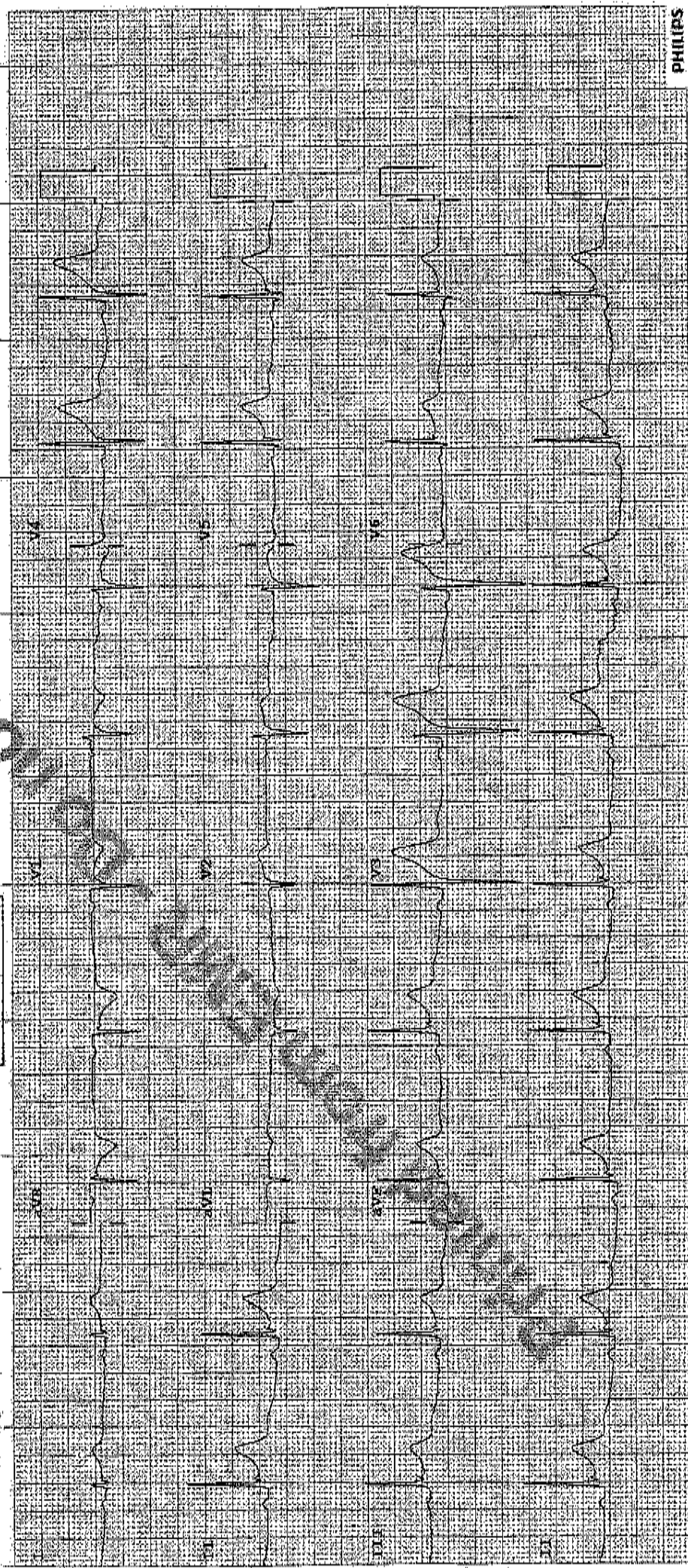
>>> Acute MI <<<

Unconfirmed Diagnosis

Room: DENNARD
Scott Edward
17 Edmonds Road
SEAFORD HEIGHTS, SA 5169

FMC-600051885
02/07/1994 M

Visit ID: 11707187 (P)
MIC: 5151632104-1
Exp: 02-24
Enrol



Device: 60CMon8 Speed: 25 mm/sec Limb: 10 mm/mv Chest: 10 mm/mv

50~ 0.15-100 Hz PH10C C P7

PHILIPS

Patient: DENNARD, Scott Edward MRN: FMC-600051885, DOB: 02 Jul 1994 Page 1 of 2

600051885 DENNARD, SCOTT EDWARD
DOB: 2-Jul-1994 28 years Male

Paced

24-Jan-2023 13:46:37

Page 1 of 1

HR 99
RR 60
PR 126
QRSD 89
QT 320
QTc 410Sinus rhythm
Inferior infarct, acute
ST elevation, consider anterior injury
Lateral wall also involved

Room

FMC-600051885
02077494 M

DENNARD

Scott Edward

17 Edmonds Road

SEAFORD HEIGHTS, SA 5169

--AXIS--

P 43
QRS 80
T 69

Visit ID: 111707167 (P)

M/C: 5151632104-1

Exp: 02-24

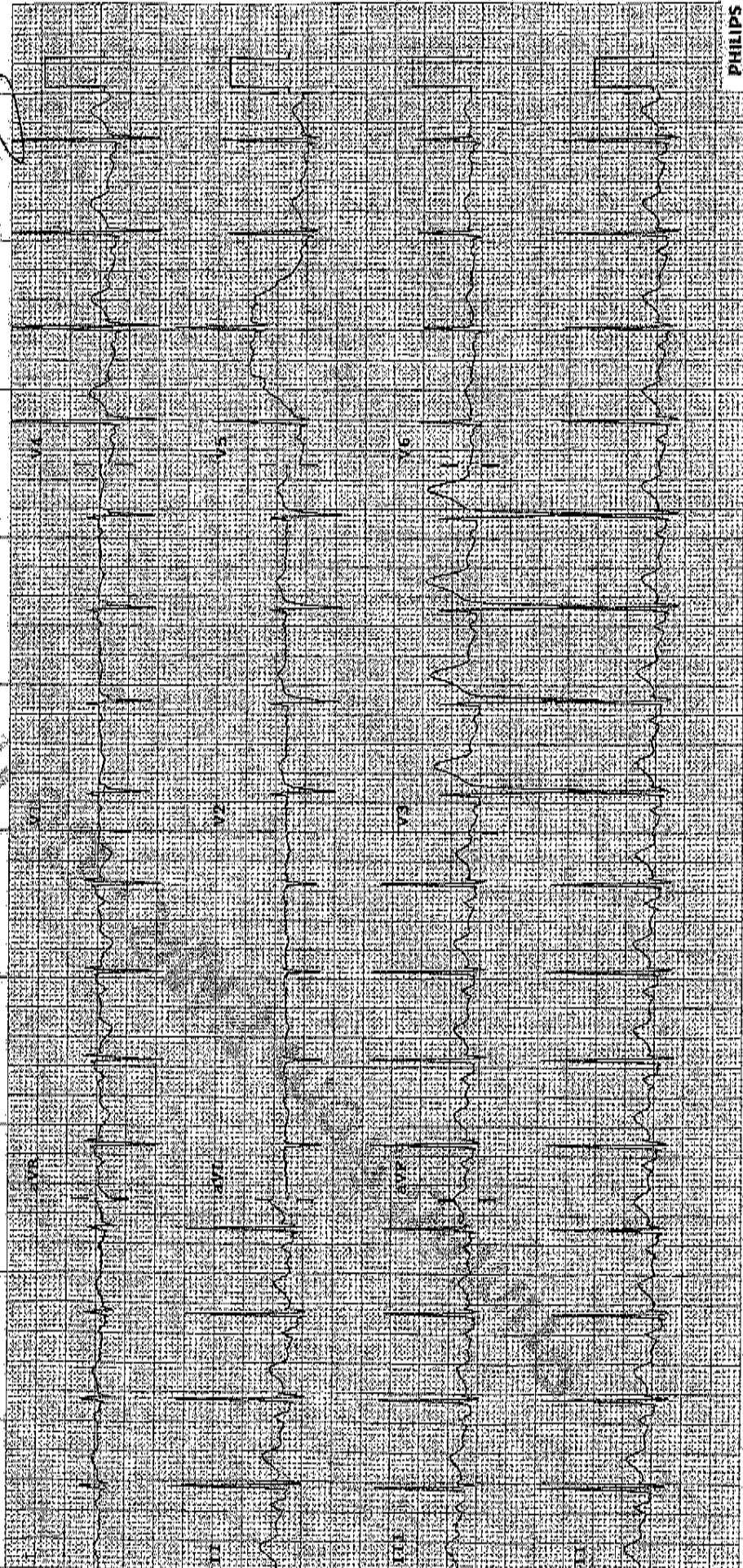
Encounter: 1

- ABNORMAL ECG -

12 Lead ECG Report (Standard)

>>> Acute MI <<<

Unconfirmed Diagnosis



Device: EDAMon10

Speed: 25 mm/sec

Chest: 10 mm/mV

0.05-150 Hz

PHILIPS

Printed By: (jmiddle03), 06 Feb 2023 10:56:00, SA Health

No Patient Admitted

Paced

24-Jan-2023 18:44:43

Page 1 of 1

HR 81
RR 736
PR 138
QRS 93
QT 361
QTc 421

--AXIS--
R 39
QRS 79
T 65

12 lead ECG Report (Mason-Likar)

>>> Acute MI <<<

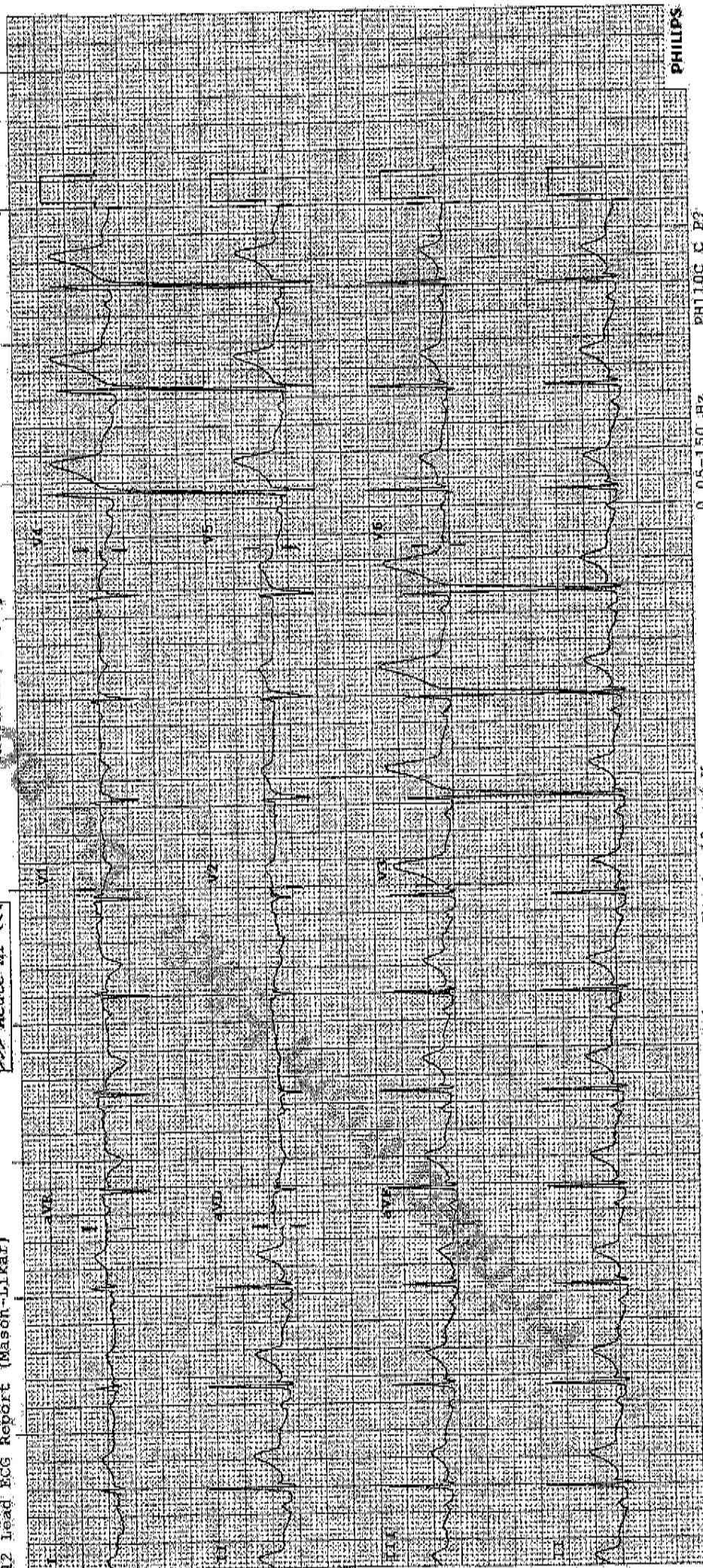
Unconfirmed Diagnosis

Room:

FMC-600051885
02/07/1994 M

DENNARD
Scott Edward
17 Edmunds Road
SEAFORD HEIGHTS, SA 5169

Visit ID: 11707167 (P)
M/G: 5161632104-1
Exp: 02-24



Device: 60CMon8

Speed: 25 mm/sec

Limbs: 10 mm/mV

Chest: 10 mm/mV

PH110C C P2

PHILIPS