

Date: 09 Sep 2021
Mr MATTHEW BRIAN
JAMES MURTAGH
DOB: 02 Sep 1986
Mobile: 081547732
Hospital Ref: 07403493

Dr Jeremy A Garman
Emergency Department
Kalgoorlie Health Campus
15 PICCADILLY STREET
KALGOORLIE
WA 6430
Phone: 0890805888
Fax: 0890805808

Dear Dr BOCK ,
Whitfords Avenue Medical Group
PO Box 812
HILLARYS WA 6023 WA
Fax : 0893076702

Mr MATTHEW BRIAN JAMES MURTAGH presented in the Emergency Department at Kalgoorlie Health Campus on 09 Sep 2021 at 07:16 with Chest Pain L) sided intermittent chest pain and ? palpitations since 4/7 post Pfizer vaccine. Non radiating. Mild SOB with pain. Denies cardiac hx. SpO2 100%, HR 67bpm.

The Diagnosis for this presentation is: Palpitations

Palpitations and chest discomfort for 4/7 post 1st dose of pfizer
NI other symptoms.

Examination unremarkable, intermittent sinus bradycardia to 50bpm

Investigations:

- CXR NAD
- Bloods (FBP/UEC/Ca/Mg/Trop) all NAD
- Serial ECG NAD (Isolated TWI lead AVL)

Plan:

- d/c home
- med cert
- GP follow-up in Perth for consideration of Thyroid function tests and holter
- If develops worsening chest pain, short of breath, fainting to seek medical attention

Date: 09 Sep 2021
Mr MATTHEW BRIAN
JAMES MURTAGH
DOB: 02 Sep 1996
Mobile: 0450947732
Hospital U/R: D7403080


Dr Jeremy A Carman

WHITFORD AVENUE MEDICAL GROUP

Dr James Setiawan
Suite 2, Whitford Ave Medical Centre
276 Dampier Avenue
KALLAROO WA 6025
Phone: 08 9307 4222
Fax: 08 9307 6702
Provider No: 2451572Y

17/9/2021

Dr Matthew Best
Cardiology
Perth Cardiovascular Institute
Hollywood Private Hospital
NEDLANDS
Phone : 63146807
Fax : 6314 6907

Re: Mast Matthew Murtagh
Address: 6 Lavinia Court, KALLAROO
DOB: 2/9/1996
Phone: 9402 1625
Mbl: 0450947732

Dear Matthew,

Thank you for seeing Matthew Murtagh, age 25yrs, for an opinion and management. He had episode of palpitation, chest pain, and shortness of breath after his pfizer injection. I would like your opinion.

Past History:

Date	Condition - Comment
1996	REFLUX - GASTRO-OESOPHAGEAL / INFANTILE
1998	ECZEMA - ALLERGIC
1998	TONSILLITIS
2000	ALLERGIC RHINITIS
2002	Otitis Media
2008	Heel pain
2008	Pes Planus (Right) with plantar enthesopathy R foot

Allergies: No known allergies/adverse reactions.

Recent Tests Xrays: Start patient : MURTAGH, MATTHEW

6 Lavinia Court, KALLAROO WA 6025

Birthdate: 02/09/1996 Age: Y25 Sex: M

Telephone: 0415 845 998

Your Reference : Shenton House

Medicare Number: 6259268682

Referred by : Dr James Setiawan

Copy To :

Addressee : Dr James Setiawan

Collected: 14/09/2021 12:00

Requested: Tuesday, 14 September 2021

Performed: Tuesday, 14 September 2021

Test name: HOLTER

Provider name: GenesisCare - HeartCare WA

2451572Y

GenesisCare - Cardiology
Level 3, 57 Shenton Avenue
JOONDALUP
WA
6027
08 9400 6161
08 9400 6100

Holter

Reference Info

Reference Date 14/09/2021
 Reference ID 6387454
 Status Final
 In Patient No
 Originator Saklani, Pradyot (Dr)

Patient Details

Patient Name MURTAGH, Matthew
 Patient ID 471620
 Gender M
 DOB 02/09/1996
 Age 25 yrs

Clinical Details

Referred by Dr James Setiawan
 Reported by Dr Pradyot Saklani
 Scientific Officer Mr Marc Eldridge

Staff List

Role Reporting MO
 Staff Name Saklani, Pradyot (Dr)
 Additional Info Reporting Doctor
 Role Scientific Officer
 Staff Name Eldridge, Marc (Mr)

Indications

Indication Notes Palpitations post pfizer

Report

Summary

UNDERLYING RHYTHM.

The resting ECG showed normally conducted sinus bradycardia.

23.5 hours of satisfactory monitoring were obtained. The dominant rhythm was sinus bradycardia with the heart rate varying between 34 and 109 beats per minute with an average rate of 56 beats per minute.

ARRHYTHMIAS.

Nil.

SYMPTOMS.

During the period of monitoring, the patient reported "fluttering/light-headed", "chest pains", "palpitations", "chest pain" which correlated with sinus rhythm or sinus bradycardia.

Conclusions

Sinus rhythm recorded during symptoms.

No significant sustained abnormality of cardiac rate or rhythm demonstrated.

Recommendations

Follow up with Dr Setiawan as arranged.

Distribution List

Distribution List 1

Doctor First Name	James
Doctor Surname	Setiawan
Doctor Title	Dr
Doctor Provider Number	2451572Y
Doctor Street1	Suite 2, Cnr Whitfords & Dampier Avenue
Suburb	KALLAROO
Postcode	6025

6 LAVINIA COURT, KALLAROO 6025
 Birthdate: 02/09/1996 Age: 25 Y Sex: M
 Telephone: 0450947732
 Your Reference : 99592-11
 CLI Reference : 433713072
 Medicare Number: 6259268682
 Phone Enquiries: Osborne Park

93714200

Referred by : Dr James Setiawan
 Addressee : Dr James Setiawan
 Lab. Reference: 433713072-H-ED- Haematology
 Requested: Saturday, 11 September 2021
 Performed: Monday, 13 September 2021
 Test name: ED- HAEMATOLOGY
 Provider name: Clinipath Pathology

2451572Y

Clinical Notes : palpitations

Haematology

Date	28/03/14	13/09/21		
Time	1705	1042		
Lab No.	437190413	433713072	Units	Reference
Haemoglobin	157	157	g/L	(130-180)
RCC	5.4	5.2	$\times 10^{12}/L$	(4.5-6.5)
Haematocrit	0.46	0.46		(0.40-0.54)
MCV	85	88	fL	(80-100)
MCH	29	30	pg	(27-32)
MCHC	341	343	g/L	(310-360)
RDW	13.0	12.0		(10-15)
WCC	7.8	6.0	$\times 10^9/L$	(4.0-11.0)
Neutrophils	4.9	3.6	$\times 10^9/L$	(2.0-7.5)
Lymphocytes	2.1	1.5	$\times 10^9/L$	(1.2-4.0)
Monocytes	0.6	0.7	$\times 10^9/L$	(0.2-1.0)
Eosinophils	0.1	0.2	$\times 10^9/L$	(0.0-0.5)
Basophils	<0.1	<0.1	$\times 10^9/L$	(0.0-0.1)
Platelets	254	250	$\times 10^9/L$	(150-400)
ESR	1	3	mm/h	(0-15)

Comments on Collection 13/09/21 1042:

FBC

The full blood count parameters are within the acceptable ranges.

Comments on Collection 28/03/14 1705:

FBC

The full blood count parameters are within the acceptable ranges.

HA

Clinipath Pathology NATA No: 2619-2612

Tests Completed: Iron Studies, C Reactive Protein, TFT, FBC, ESR, IGA CDS

Tests Pending : COELIAC SEROLOGY

Sample Pending :

Start Patient : MURTAGH, MATTHEW
 6 LAVINIA COURT, KALLAROO 6025
 Birthdate: 02/09/1996 Age: 25 Y Sex: M
 Telephone: 0450947732
 Your Reference : 99592-11
 CLI Reference : 433713072
 Medicare Number: 6259268682
 Phone Enquiries: Osborne Park

93714200

Referred by : Dr James Setiawan
 Addressee : Dr James Setiawan
 Lab. Reference: 433713072-I-SE- CDS SEROLOGY
 Requested: Saturday, 11 September 2021
 Performed: Monday, 13 September 2021

2451572Y

Test name: SE- CDS SEROLOGY
Provider name: Clinipath Pathology

Clinical Notes : palpitations

Coeliac Serology

Date 13/09/21
Time 1042
Lab No. 433713072

		Units	Reference
tTG IgA	1.	U/mL	(<7)
DGP IgG	1	U/mL	(<7)
IgA	2.0	g/L	(0.7-4.0)

Comments on Collection 13/09/21 1042:

Coeliac disease is very unlikely in patients on a gluten containing diet*. If a strong clinical suspicion remains or there is a family history, Coeliac Disease tissue typing (HLA-DQ2/8) or small bowel biopsy may help exclude the disease further.

*patients should be on a gluten containing diet (gluten intake equivalent to four slices of wheat bread a day) for 6-12 weeks for optimal sensitivity of antibody tests.

HA

Clinipath Pathology NATA No: 2619-2612

Tests Completed: Iron Studies, C Reactive Protein, TFT, FBC, ESR,
COELIAC SEROLOGY, IGA CDS

Tests Pending :
Sample Pending :

Start Patient : MURTAGH, MATTHEW
6 LAVINIA COURT, KALLAROO 6025
Birthdate: 02/09/1996 Age: 25 Y Sex: M
Telephone: 0450947732
Your Reference : 99592-11
CLI Reference : 433713072
Medicare Number: 6259268682
Phone Enquiries: Osborne Park

93714200

Referred by : Dr James Setiawan
Addressee : Dr James Setiawan
Lab. Reference: 433713072-C-SE-
Requested: Saturday, 11 September 2021
Performed: Monday, 13 September 2021
Test name: SE- THYROID FUNCTION
Provider name: Clinipath Pathology

2451572Y

Clinical Notes : palpitations

Thyroid Function

Date 13/09/21
Time 1042
Lab No. 433713072

		Units	Reference
TSH	1.12	mU/L	(0.4-4.0)

Comments on Collection 13/09/21 1042:

TFT
Euthyroid levels.

CA

Clinipath Pathology NATA No: 2619-2612

Tests Completed: Iron Studies, C Reactive Protein, TFT, FBC, ESR, IGA CDS
Tests Pending : COELIAC SEROLOGY
Sample Pending :

Start Patient : MURTAGH, MATTHEW
6 LAVINIA COURT, KALLAROO 6025
Birthdate: 02/09/1996 Age: 25 Y Sex: M
Telephone: 0450947732
Your Reference : 99592-11
CLI Reference : 433713072
Medicare Number: 6259268682
Phone Enquiries: Osborne Park 93714200

Referred by : Dr James Setiawan
Addressee : Dr James Setiawan 2451572Y
Lab. Reference: 433713072-C-SE-CRP
Requested: Saturday, 11 September 2021
Performed: Monday, 13 September 2021
Test name: SE-C REACTIVE PROTEIN
Provider name: Clinipath Pathology

Clinical Notes : palpitations

Date	Time	Lab No.	Units	Reference
13/09/21	1042	433713072		
CRP		3	mg/L	(<5)

Comments on Collection 13/09/21 1042:
C Reactive Protein

CA

Clinipath Pathology NATA No: 2619-2612

Tests Completed: C Reactive Protein, FBC, IGA CDS
Tests Pending : Iron Studies, TFT, ESR, COELIAC SEROLOGY
Sample Pending :

Start Patient : MURTAGH, MATTHEW
6 LAVINIA COURT, KALLAROO 6025
Birthdate: 02/09/1996 Age: 25 Y Sex: M
Telephone: 0450947732
Your Reference : 99592-11
CLI Reference : 433713072
Medicare Number: 6259268682
Phone Enquiries: Osborne Park 93714200

Referred by : Dr James Setiawan
Addressee : Dr James Setiawan 2451572Y
Lab. Reference: 433713072-C-SE- FE STUDIES
Requested: Saturday, 11 September 2021
Performed: Monday, 13 September 2021
Test name: SE-IRON STUDIES
Provider name: Clinipath Pathology

Clinical Notes : palpitations

Iron Studies

Date	Time	13/09/21
28/03/14	1705	1042

start patient : MURTAGH, MATTHEW
6 Lavinia Court, KALLAROO WA 6025
Birthdate: 02/09/1996 Age: Y25 Sex: M
Telephone: 0415 845 998
Your Reference : Shenton House
Medicare Number: 6259268682
Referred by : Dr James Setiawan
Copy To :
Addressee : Dr James Setiawan 2451572Y
Collected: 13/09/2021 01:31
Requested: Monday, 13 September 2021
Performed: Monday, 13 September 2021
Test name: ECHOCARDIOGRAM
Provider name: GenesisCare - HeartCare WA

GenesisCare - Cardiology
Level 3, 57 Shenton Avenue
JOONDALUP
WA
6027
08 9400 6161
08 9400 6100

Echocardiogram

=====

Patient Details

Patient Name MURTAGH, Matthew
Patient ID 471620
Gender M
DOB 02/09/1996
Age 25 yrs
=====

Reference Info

Reference Date 13/09/2021
Reference ID 6381916
Status Final
In Patient No
Originator Tan, Isabel (Dr)
=====

Clinical Details

BSA 1.87
Height 180 cm
Weight 70 kg
BMI 21.6
Referred by Dr James Setiawan
Reported by Dr Isabel Tan
Scientific Officer Mr Vincent Louise
=====

Staff List

Staff List 1

Role Reporting MO
Staff Name Tan, Isabel (Dr)
Additional Info Reporting Doctor
=====

Staff List 2

Role Sonographer
Staff Name Louise, Vincent (Mr)
=====

Indications

Recurring palpitations post pfizer injection
=====

Presenting

Rhythm Sinus rhythm
=====

MMode / 2D

LV Diastole (42-58)	55 mm
LV diastole () (22-30)	29.4 mm/m2
LV diastole ()	30.6 mm/m
LV Systole (25-40)	33 mm
IV Septum (6-10)	7 mm
Inferolateral Wall (6-10)	8 mm
TAPSE (>16)	24 mm
Aortic Root (31-37)	32 mm
LV Mass (2D) (96-200)	147 g
LV Mass () (50-102)	78.6 g/m2

2D

LV EDV (62-150)	122 mL
LV EDV () (34-74)	65.2 mL/m2
LV ESV (21-61)	52 mL
LV ESV () (11-31)	27.8 mL/m2
EF (mod.Simp) (52-72)	57 %
LV Stroke Volume	70 mL
LA Area 2 chamber (<=20)	18 cm2
LA Volume	55 ml
LA Volume (indexed) (16-34)	29.4 ml/m2
RA Area (<=18)	10.5 cm2
LV Stroke Volume () (33-47)	37.4 mL/m2/beat

Pulmonary Valve

Peak Velocity	1.2 m/s
Peak Gradient	6 mmHg

Aortic Valve

LVOT Diameter	2.1 cm
LVOT VTI	21.8 cm
LVOT Velocity	1.1 m/sec
Peak Velocity (A)	1.3 m/sec
Peak Gradient (A)	7 mmHg
Mean Gradient (A)	4 mmHg
AV VTI	28.9 cm
AVA (Cont.)	2.5 cm2
AVA Index	1.34 cm2/m2
DPI	0.75

Regurgitation

Peak TR Velocity	2.2 m/s
Peak TR Gradient	19 mmHg
RA Pressure	3 mmHg
RVSP	23 mmHg

Diastology

Mitral Valve Doppler

E Velocity	0.8 m/sec
Deceleration Time	187 ms
A Velocity	0.4 m/sec
E:A Ratio	2

Mitral Valve

E Velocity	0.8 m/sec
A Velocity	0.4 m/sec
E:A Ratio	2
Deceleration Time	187 ms

Aortic Valve Doppler

LVOT Diameter	2.1 cm
LVOT Integral	21.8 cm
LVOT Velocity	1.1 m/sec
Peak Velocity	1.3 m/sec
Peak Gradient	7 mmHg
Mean Gradient	4 mmHg

AVA 2.5 cm2
AVA Index 1.34 cm2/m2
DPI 0.75

=====

Tricuspid Valve Doppler

Peak TR Velocity 2.2 m/sec
RA Pressure 3 mmHg
RVSP 23 mmHg

=====

Pulmonary Valve Doppler

Max Velocity 1.2 m/sec
Max Gradient 6 mmHg

=====

Report

Summary

Left Ventricle

Left ventricular size and systolic function are normal. There are no obvious regional wall motion abnormalities. The EF = 57% by Simpson's biplane. Diastolic function is normal.

Left Atrium

The left atrium is of normal size. No evidence of shunt via colour Doppler interrogation.

Mitral Valve

The mitral valve leaflets are thin and mobile. No significant regurgitation visualised by Doppler.

Aortic Valve, Aorta

The aortic valve is trileaflet and there is no Doppler evidence of aortic stenosis or regurgitation.

Right Ventricle, Tricuspid Valve

Right ventricular size and function are normal. The tricuspid valve is normal. There is Doppler evidence of trace tricuspid regurgitation. The peak tricuspid regurgitation velocity is 2.2m/sec, corresponding to a pulmonary artery pressure of 23mmHg (assuming RA pressure = 3mmHg).

Right Atrium, Vena Cava

The right atrium is normal. The IVC is normal size and collapses with inspiration.

Pulmonary Artery / Valve
Normal.

Pericardium, Shunts, Other
Normal.

Conclusions

Normal left and right ventricular size and systolic function.
No haemodynamically significant valvular dysfunction.
No echocardiographic evidence of myocarditis/pericarditis.

=====

Distribution List

Distribution List 1

Doctor First Name	James
Doctor Surname	Setiawan
Doctor Title	Dr
Doctor Provider Number	2451572Y
Doctor Street1	Suite 2, Cnr Whitfords & Dampier Avenue
Suburb	KALLAROO
Postcode	6025

Start Patient : MURTAGH, MATTHEW

ESR

1

3

3

mm/h

(0-15)

Comments on Collection 17/01/22 1146:
FBC

The full blood count parameters are within the acceptable ranges.

Comments on Collection 13/09/21 1042:
FBC

The full blood count parameters are within the acceptable ranges.

Comments on Collection 28/03/14 1705:
FBC

The full blood count parameters are within the acceptable ranges.

HA

Clinipath Pathology NATA No: 2619-2612

Tests Completed: C Reactive Protein, hs Troponin I, FBC, ESR

Tests Pending :

Sample Pending :

Start Patient : MURTAGH, MATTHEW

6 LAVINIA COURT, KALLAROO 6025

Birthdate: 02/09/1996 Age: 25 Y Sex: M

Telephone: 0450947732

Your Reference : 805051650860

CLI Reference : 435502900

Medicare Number: 6259268682

Phone Enquiries: Osborne Park 93714200

Referred by : Dr James Setiawan

Copy To : Dr Matthew Best

Addressee : Dr James Setiawan 2451572Y

Lab. Reference: 435502900-C-SE-TROP

Requested: Saturday, 15 January 2022

Performed: Monday, 17 January 2022

Test name: SE-

Provider name: Clinipath Pathology

Clinical Notes : chest pain. pericarditisi. post pfizer.

Troponin

Date 17/01/22

Time 1146

Lab No. 435502900

Units Reference

hs Troponin I <1

ng/L (<26)

Comments on Collection 17/01/22 1146:

hs Troponin I

Most healthy individuals have detectable troponin I (TnI) with the Abbott Alinity high sensitive assay. Causes of elevated Tn I include acute coronary syndrome (ACS) or CCF, arrhythmias, renal failure, pulmonary embolism and myocarditis. A diagnosis of ACS requires at least one elevated TnI value with ischaemic symptoms or typical ECG changes.

CA

Clinipath Pathology NATA No: 2619-2612

Tests Completed: C Reactive Protein, hs Troponin I, FBC, ESR

Tests Pending :

Sample Pending :

Start Patient : MURTAGH, MATTHEW

6 LAVINIA COURT, KALLAROO 6025

Birthdate: 02/09/1996 Age: Y25 Sex: M
Telephone: 94021625

Your Reference :
Lab Reference : 22-88688931
Medicare Number: 6259268682
Phone Enquiries:

Referred By... : DR M BEST
Copy To... : DR J SETIAWAN
Addressee : DR. JAMES SETIAWAN
Lab. Reference: 22-88688931-CRP-0 2451572Y
Requested: Wednesday, 2 March 2022
Performed: Wednesday, 2 March 2022
Test name: C-REACTIVE PROTEIN (CRP) (CRP-0)
Provider name: WESTERN DIAGNOSTIC PATHOLOGY

C-REACTIVE PROTEIN (Serum) (Reference Range < 5)

Date	Time	Result mg/L	Lab. No.
02/03/22	00:00	< 1	88688931

Please note: Reference range change as of 17th March 2015.

Requested Tests : HST*, CRP

Start Patient : MURTAGH, MATTHEW
6 LAVINIA COURT, KALLAROO 6025
Birthdate: 02/09/1996 Age: 25 Y Sex: M
Telephone: 0450947732
Your Reference : 805051650860
CLI Reference : 435502900
Medicare Number: 6259268682
Phone Enquiries: Osborne Park 93714200

Referred by : Dr James Setiawan
Copy To : Dr Matthew Best
Addressee : Dr James Setiawan 2451572Y
Lab. Reference: 435502900-H-ED- Haematology
Requested: Saturday, 15 January 2022
Performed: Monday, 17 January 2022
Test name: ED- HAEMATOLOGY
Provider name: Clinipath Pathology

Clinical Notes : chest pain. pericarditisi. post pfizer.

Haematology

Date	28/03/14	13/09/21	17/01/22	Units	Reference
Time	1705	1042	1146		
Lab No.	437190413	433713072	435502900		
Haemoglobin	157	157	161	g/L	(130-180)
RCC	5.4	5.2	5.3	x10 ¹² /L	(4.5-6.5)
Haematocrit	0.46	0.46	0.45		(0.40-0.54)
MCV	85	88	86	fL	(80-100)
MCH	29	30	31	pg	(27-32)
MCHC	341	343	356	g/L	(310-360)
RDW	13.0	12.0	12.1		(10-15)
WCC	7.8	6.0	5.7	x10 ⁹ /L	(4.0-11.0)
Neutrophils	4.9	3.6	2.9	x10 ⁹ /L	(2.0-7.5)
Lymphocytes	2.1	1.5	2.0	x10 ⁹ /L	(1.2-4.0)
Monocytes	0.6	0.7	0.4	x10 ⁹ /L	(0.2-1.0)
Eosinophils	0.1	0.2	0.4	x10 ⁹ /L	(0.0-0.5)
Basophils	<0.1	<0.1	<0.1	x10 ⁹ /L	(0.0-0.1)
Platelets	254	250	234	x10 ⁹ /L	(150-400)

Copy To.. : DR J SETIAWAN
Addressee : DR. JAMES SETIAWAN
Lab. Reference: 22-88688931-HST-0
Requested: Wednesday, 2 March 2022
Performed: Wednesday, 2 March 2022
Test name: HIGH SENSITIVITY TROPONIN (HST-0)
Provider name: WESTERN DIAGNOSTIC PATHOLOGY

2451572Y

High Sensitive Troponin I (hsTnI) - Serum/Plasma

Date of Collection: 02/03/2022
Time of Collection: na
Lab No: 22-88688931

hsTnI (Beckman Coulter): 2 (<21
ng/L)

Z-Score:

Time since last hsTnI collected: /
(HH:MM)

Delta change since last hsTnI: /
(ng/L)

significant * Z-score > +/- 2.0 indicates >95% prob of
change.
significant * Z-score > +/- 3.0 indicates >99% prob of
change.
(M) * Normal hs-Troponin is 0-10 ng/L (F) and 0-20 ng/L

fall) in * A diagnosis of AMI requires a change (rise or
gender-specific Troponin with at least one value above the
ischaemic reference interval in the presence of suggestive
symptoms and/or ECG changes.
AMI. * Troponin may be increased by causes other than
different Caution should be used in comparing results from
instruments as standardisation varies.

Requested Tests : HST, CRP

Start Patient : MURTAGH, MATTHEW
6 LAVINIA CT, KALLAROO, WA 6025

EY
HAM

Medicare No.:
Lab. Reference: WVL10454653-CT CHEST
Requested By: DR JAMES SETIAWAN
Requested: Wednesday, 2 March 2022
Performed: Friday, 4 March 2022
Test name: CT CHEST +/- UPPER ABDOMEN PRE/POST CONTRAST
Provider name: SKG

Apollo RIS Patient Id : SKG1032644

Patient Name : MURTAGH MATTHEW DOB : 02/09/1996 Service Date : 04/03/2022

CT CHEST WITH CONTRAST

Clinical History: Atypical chest pain. Now ongoing post Pfizer vaccine back in September 2021. Wakes each morning with chest pain. Exclude non-cardiac pathology.

Findings: No pleural effusion, pericardial effusion, lymphadenopathy, mass, or lung abnormality is identified.

No significant abnormality of the major mediastinal vessels or heart or suspicious osseous lesion is seen. Images of the upper abdomen are without an abnormal fluid collection or mass seen.

Comment: No significant abnormality is identified.

Thank you for your referral.

Yours sincerely,

Dr Karl Wolff - SKG Radiology

CC :

Dr Setiawan James , Suite 2, Cnr Dampier & Whitfords Ave, Kallaroo WA 6025

To view your patient images, please use the following link;

Click [here](#)

We are telehealth ready - visit <https://skg.com.au/referrers/skg-radiology-telehealth/> for referrer guide and telehealth forms.

For more information, please email referrer.services@skg.com.au

 SKG

Start Patient : MURTAGH, MATTHEW
6 LAVINIA CT, KALLAROO, WA 6025
Birthdate: 02/09/1996 Age: Y25 Sex: M
Telephone: 94021625

Your Reference :
Lab Reference : 22-88688931
Medicare Number: 6259268682
Phone Enquiries:

Referred By... : DR M BEST

Lab No.	437190413	433713072	Units	Reference
Iron	18	22	umol/L	(5-30)
Transferrin	36	34	umol/L	(25-40)
Saturation	25	32	%	(10-45)
Ferritin	41	50	ug/L	(30-500)

CA

Clinipath Pathology NATA No: 2619-2612

Tests Completed: Iron Studies, C Reactive Protein, TFT, FBC, ESR, IGA CDS
Tests Pending : COELIAC SEROLOGY
Sample Pending :

Yours faithfully,

Dr James Setiawan.
M.B.B.S.F.R.A.C.G.P.



PRIVATE AND CONFIDENTIAL

17th December 2021

Dr James Setiawan
Whitfords Avenue Medical Group
Suite 2, 276 Dampier Avenue
KALLAROO WA 6025

Dear James

RE: Matthew Murtagh DOB: 2/9/1996
6 Lavinia Court
KALLAROO, WA 6025

I saw Matt today. He has done his three months of Colchicine. He still has some residual chest discomfort but it is nowhere near as bad as it was. This probably relates to pericarditis, at least that is the working diagnosis. I do not have a better one.

On the other hand, however, he has gut side effects and he has done three months so I have advised him to stop the Colchicine.

The big issue of course is does he have his second COVID vaccine i.e. Pfizer, and at this point in time Matthew is disinterested and that is completely understandable.

I have written him a letter saying that he has likely had an adverse reaction of significance from the first Pfizer vaccine and is therefore medically exempt.

Medically probably his best option is for his second vaccine to be the Novavax vaccine. However, at the moment, or at least at time of dictation, to the best of my knowledge that is not available in Australia.

I worry that political pressure will mount on Matthew that we will have to reconsider that decision about the second Pfizer vaccine, but we will see what time tells us.

Yours sincerely,

Electronically approved by Dr Matthew Best
Cardiologist
Perth Cardiovascular Institute
TEL: 08 6314 6807 | FAX: 08 6314 6907 | MOB: 0404 039 947

MOUNT HOSPITAL
HOLLYWOOD SPECIALIST CENTRE
JOONDALUP HEALTH CAMPUS
ST JOHN OF GOD MURDOCH

BENTLEY
ESPERANCE

KIMBERLEY
MIDLAND

MT LAWLEY
ROCKINGHAM

3x4 Simultaneous ECG Report

Patient Details

Name: Matthew Murtagh
ID: 31190
Gender: Male
Date of Birth: 2/09/1996 (25 years)
Height: 180 cm
Weight: 45 kg

Recording Details

Recorded: 15/01/2022 2:05:41 PM
Device: CL 501521

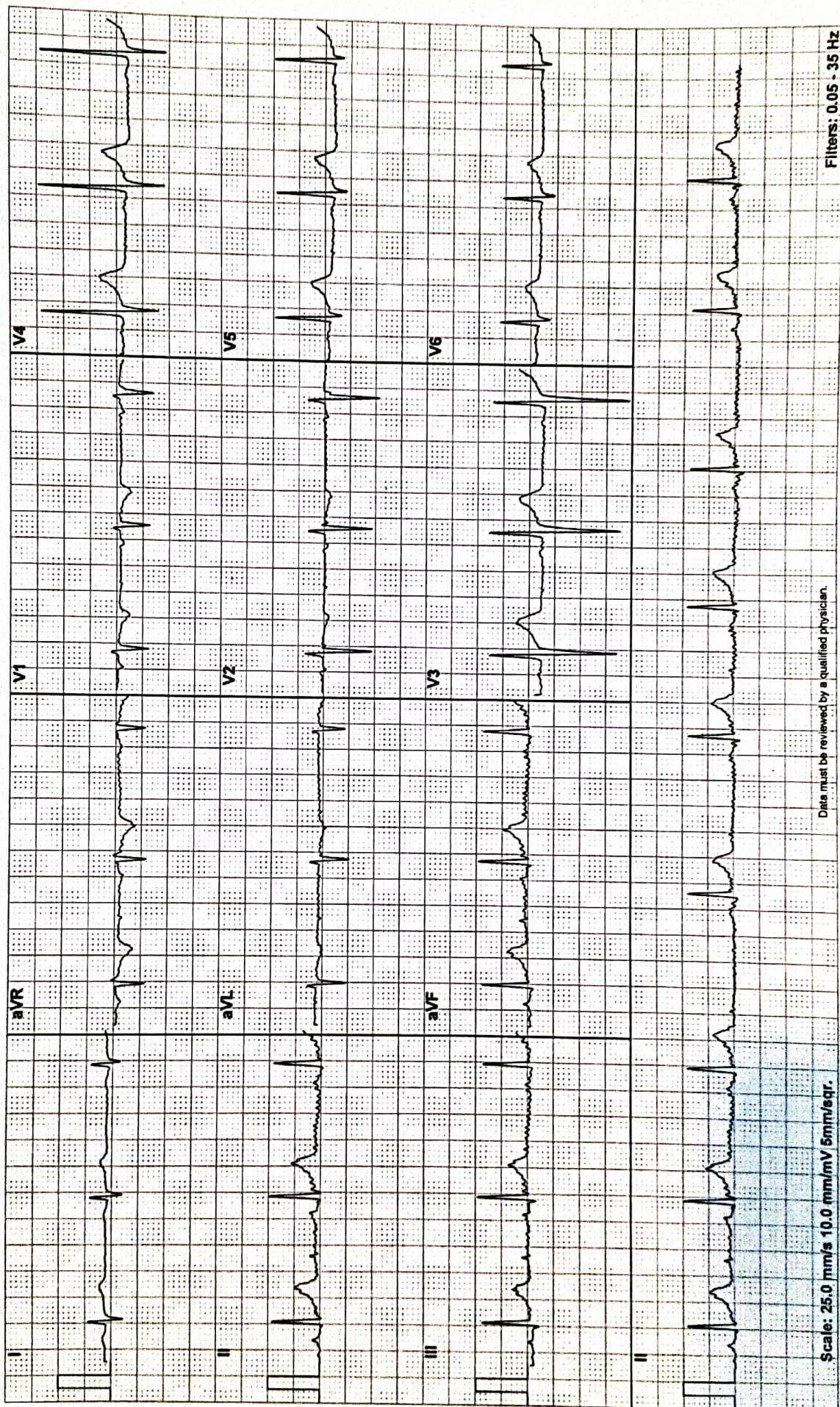
Measurements

Heart Rate: 55 bpm
P Duration: 114 ms
PR Interval: 160 ms
QRS Duration: 92 ms
QT Interval: 396 ms
QTc Interval: 380 ms (Bazett)
P, QRS, T Axis: 53°, 85°, 75°

Interpretation (Unconfirmed)

005 Sinus bradycardia
030 Sinus arrhythmia
035 Atrial fibrillation cannot be ruled out
275 Abnormal repolarisation, possible coronary ischemia

Comments:



Scale: 25.0 mm/s 10.0 mm/mV 5mm/sqr.

Data must be reviewed by a qualified physician.

Office Medic Version: 5.0.2.0, Copyright VectraCor, Inc.

Filters: 0.05 - 35 Hz

Patient Name: MURTAGH, MATTHEW
Patient Address: 6 LAVINIA COURT, KALLAROO 6025
D.O.B: 2/09/1996
Gender: M
Medicare No.:
IHI No.:
Lab. Reference: 704567
Provider: Dr Matthew Best
Addressee: Dr James Setiawan
Referred by: Dr Matthew Best
Date Requested:
Date Performed: 24/12/2021
Date Collected: 24/12/2021
Completer: Final
Specimen:
Subject(Test Name): RSD - Medical



Government of Western Australia
North Metropolitan Health Service
Sir Charles Gairdner Osborne Park Health Care Group



Department of Immunology
Tel. No. 08 6457 1490
Clinic Date: 31/12/2021

Dr Russell J. Bock
Whitfords Avenue Medical Group
PO Box 312
HILLARYS WA 6923

Dear Dr Bock

Patient Name: Matthew MURTAGH

UMRN: D7403080
DOB: 2/9/1996

I reviewed Matthew in the Vaccine Safety Clinic today. He was accompanied by his mother. Matthew is 25-year-old. He has no significant past medical history and no known allergies.

Matthew received his first Pfizer vaccine dose on 06 September 2021. This was initially uncomplicated. Three to four days after the injection, however, he developed pericarditic chest pain and palpitations. He presented to hospital the next day and was assessed. He had negative serial troponins and a relatively unremarkable ECG. He later had an echocardiogram which was also normal.

Following his discharge from hospital, Matthew was reviewed by Dr Matthew Best, Cardiologist. Dr Best's review suggested that the most likely diagnosis was that of pericarditis.

I agree that Matthew's description of his chest pain, the time of onset following his Pfizer vaccine dose, his risk factors (young, male) and the lack of an apparent alternative cause for his symptoms suggest that mRNA vaccine induced pericarditis is the most likely diagnosis. Despite this, Matthew would be considered a Brighton classification level 4 or 5 due to the overall lack of objective findings.

Matthew was treated with colchicine for a period, although as of now, almost three months down the line, he continues to have intermittent chest pains. Fortunately, these are milder than previous, and overall, the trajectory remains that of gradual improvement.

We discussed that the rate of recurrence of pericarditis following re-exposure to mRNA vaccines is unknown, but it is clear that in many cases it is tolerated. Indeed, the current ATAGI guidelines would suggest that Matthew can pursue a further mRNA vaccine dose after his pain has settled (given his last vaccine dose was >6 weeks ago). Therefore, his ongoing pain is the only barrier to further vaccination at this stage.

We discussed that, other than waiting for his lingering symptoms to settle, the other option would be pursue immunisation with another vaccine in the meantime. The only currently available alternative is the AstraZeneca vaccine, which is not associated with an increased incidence of pericarditis. Matthew has no contraindications towards AstraZeneca; the benefits of vaccination would be considered to outweigh the risks.

Sir Charles Gairdner Hospital, Hospital Avenue, NEDLANDS, Western Australia 6009
Telephone (08 6457 3333
www.scgh.health.wa.gov.au

If Matthew wished for an exemption from AstraZeneca as well, he would need to apply to the Chief Health Officer directly. It is likely that such an exemption would only be the temporary, and that it would be revoked in the setting of sustained community transmission of COVID.

Please contact us if there are any further queries.

Yours sincerely

Electronically approved by

Dr Matthew Krummenacher
Advanced Trainee

cc: Dr Matthew J. Best, Cardiologist, Perth Cardiovascular Institute, PO Box 342, NEDLANDS WA 6909
Mr Matthew B. Murtagh,



PRIVATE AND CONFIDENTIAL

2nd March 2022

Dr James Setiawan
Whitfords Avenue Medical Group
Suite 2 / 276 Dampier Avenue
KALLAROO WA 6025

Dear James

RE: Matthew Murtagh DOB: 2/9/1996
6 Lavinia Court
KALLAROO, WA 6025

I caught up with Matthew today. When I saw him in December (of which I was completely up front with him about) he appeared really grumpy and really unhappy, so I was not looking forward to seeing him today but he was in a bright cheery mood. He tells me that in December he was quitting smoking so that is probably why he was grumpy!

Now Matthew's CRP and troponins have settled right down and he is not taking any real anti-inflammatories apart from low dose aspirin 100 mg a day which I have advised him to stop. He is currently on some antihistamines and he feels they might be helping. I really cannot explain his chest pain. It is this central band like chest pain down the front of his chest almost in a reflux type pattern but it is not reflux. It is not associated with spicy foods, tomatoes or onions, alcohol and there is no bad taste in the back of his mouth. He occasionally also gets this localised left-sided chest pain which again does not sound cardiac.

He has got sensation of a forceful beat but that is awareness of self.

I would like to do a CT of his chest to exclude a non-cardiac pathology here. I had one case recently where pericarditis was triggered by non-Hodgkin's lymphoma! I have given Matthew a request for a CT scan and he will shop around for a low-cost provider somewhere near Kallaroo.

I will recheck his troponin and CRP but with those ones in January being normal these ones are likely to be normal. When they are normal, the yield of a cardiac MRI is going to be very low and I have explained this to Matthew today.

Despite my reassurance he is very keen to get an MRI done and I have told him that he can get a good MRI in Madeley at Western Radiology and they give a pretty good price, it is \$395. It is pretty much the best he is going to get in Perth. Matthew is very keen to get that MRI done despite my reassurance so we will get some bloods, a CT and an MRI done and I will Telehealth him with the results.

Yours sincerely,

MOUNT HOSPITAL
HOLLYWOOD SPECIALIST CENTRE
JOONDALUP HEALTH CAMPUS
ST JOHN OF GOD MURDOCH

BENTLEY
ESPERANCE

KIMBERLEY
MIDLAND

MT LAWLEY
ROCKINGHAM

Electronically approved by Dr Matthew Best
Cardiologist
Perth Cardiovascular Institute
TEL: 08 6314 6807 | FAX: 08 6314 6907 | MOB: 0404 039 947
Healthlink: pcardins

MOUNT HOSPITAL
HOLLYWOOD SPECIALIST CENTRE
JOONDALUP HEALTH CAMPUS
ST JOHN OF GOD MURDOCH

BENTLEY
ESPERANCE

KIMBERLEY
MIDLAND

MT LAWLEY
ROCKINGHAM



PRIVATE AND CONFIDENTIAL

10th March 2022

Dr James Setiawan
Whitfords Avenue Medical Group
Suite 2 / 276 Dampier Avenue
KALLAROO WA 6025

Dear James

RE: Matthew Murtagh DOB: 2/9/1996
6 Lavinia Court
KALLAROO, WA 6025

I had a Telehealth with Matthew. Now importantly his CT of his chest is totally normal. There is no pericardial thickening, no signs of pericardial constriction, no signs of a sinister diagnosis causing his chest pain so that is good news.

I think Matt made a good decision to have the MRI. Now again the pericardium is normal, no oedema, no late enhancement, it is all normal and there is a small focus of subepicardial fibrosis that is consistent with previous myocarditis but there is no oedema to suggest ongoing inflammation.

I think this suggests that something happened to Matt in September but with the MRI not showing any signs of ongoing inflammation, the CT scan not showing any signs of inflammation and his troponin and CRP normal, I now officially have no answer as to why he has got this ongoing atypical chest pain.

It is not classic for reflux. It might be reasonable considering an endoscopy or a trial of a PPI but I am not pushing those. I have encouraged Matt to follow up with you because I am now fully, fully cardiac tested him James and I cannot really get to the bottom of this chest pain, with apologies. I expressed my frustration to Matt. He took it well and he promised to let me know if a diagnosis is found!

Yours sincerely,

Electronically approved by Dr Matthew Best
Cardiologist
Perth Cardiovascular Institute
TEL: 08 6314 6807 | FAX: 08 6314 6907 | MOB: 0404 039 947
Healthlink: pcardins

MOUNT HOSPITAL
HOLLYWOOD SPECIALIST CENTRE
JOONDALUP HEALTH CAMPUS
ST JOHN OF GOD MURDOCH

BENTLEY
ESPERANCE

KIMBERLEY
MIDLAND

MT LAWLEY
ROCKINGHAM

Name: Murtagh, Matthew
Address: 6 Lavinia Court
KALLAROO. 6025
D.O.B.: 02/09/1996 Gender: M
Medicare No:
IHI No:

Lab. Reference: 743455
Date Requested: 10/03/2022
Addressee: Dr James Setiawan
Referred by: Dr Matthew Best
Collected: 10/03/2022 00:00
Specimen:
Test Name: Cardiologist Outbound Correspondence
Clinical Information:

Cardiologist Outbound Correspondence
Lab. Reference: 743455
Requested: 10/03/2022
Complete: Final
Collected: 10/03/2022
pcardIns

Demographics and Contact Details

Person:

Name:	Murtagh, Matthew
Address:	6 Lavinia Court KALLAROO. 6025
D.O.B.:	02/09/1996
Gender:	M
Medicare No:	

Person or Organization

Referred to Provider	Dr James Setiawan
Referring Provider	Dr Matthew Best

Facility Location:

Referree
Suite 2 / 276 Dampier Avenue KALLAROO 6025

Referrer
Perth Cardiovascular Institute

Discharge Information Type:

Completion Status:	Pending	
Type:	MEDICAL	
Priority:		Routine
Disposition:		

Referral Reason:

Investigations

Lab. Reference:	743455
Complete:	Final
Cardiologist Outbound Correspondence	

Patient Name: MURTAGH, MATTHEW
Patient Address: 6 LAVINIA COURT, KALLAROO 6025
D.O.B: 2/09/1996 **Gender:** M
Medicare No.: **IHI No.:**
Lab. Reference: 740651 **Provider:** Dr Matthew
Best
Addressee: Dr James Setiawan **Referred by:** Dr Matthew
Best

Date Requested: **Date Performed:** 10/03/2022
Date Collected: 10/03/2022 **Complete:** Final
Specimen:
Subject(Test Name): RSD - Medical



**ST VINCENT'S
HOSPITAL**
SYDNEY

A FACILITY OF ST VINCENT'S HEALTH AUSTRALIA

St Vincent's Hospital Sydney Limited
ABN 77 054 038 872
380 Victoria Street
Darlinghurst NSW 2010
Telephone 02 8382 1111
Facsimile 02 9332 4142
www.stvincents.com.au

:IMedX

28 April 2022

Dr James Setiawan
Whitfords Avenue Medical Group
Suite 2/276 Dampier Ave
KALLAROO WA 6025

Dear Dr Setiawan,

RE: Matthew Murtagh DOB: 2/9/1996 MRN: 6264514 Gender: M

Thank you for referring Matt to the IBAC Clinic

He is a 25-year-old man with a probable post-COVID vaccine myocarditis. He had first dose Pfizer vaccine on 5 September 2021, with no significant acute adverse effects of vaccination. However, four days post-vaccine he developed quite marked palpitations and chest pain. He has had no further vaccinations. He had a cardiologist review around four weeks later due to ongoing symptoms and apparently had a normal echocardiogram. He has also had a recent cardiac MRI (10 March, which apparently showed no evidence of active inflammation but a small focus of fibrosis consistent with prior myocarditis.

Currently, he has ongoing palpitations which he describes as a "strong thudding", as well as chest discomfort, particularly in the mornings. His overall symptoms have slowly improved, moving from daily to around three times per week episodes. He also has associated dizziness and lethargy. He has postexertional fatigue even with a relatively low activity level such as a walk for 1 or 2 km. Clearly he is very anxious about his current condition.

He is single with no children, lives in Perth and was working as a surveyor but has not been working last few months. He smokes three cigarettes a day. He has had minimal alcohol intake recently.

His only regular medication is Zyrtec 1 daily, although he does take Nurofen as needed.

Overall, I believe he has had a Pfizer vaccine-related myocarditis. I have reassured him that he should continue to improve; there is no specific therapy that is required and no evidence of potential long-term cardiac damage.

UNDER THE STEWARDSHIP OF MARY AIKENHEAD MINISTRIES

St Vincent's Health Network Sydney
St Vincent's Hospital Sydney
Sacred Heart Health Service
St Joseph's Hospital

I will review him again in four or five weeks.

Yours sincerely,

Electronically Approved by:
Professor Greg Dore
Infectious Diseases Physician
Viral Hepatitis Service

Appointments: Ph: 83822575 Fax: 83822090

gdore@kirby.unsw.edu.au



Department of Immunology
Tel. No. 08 6457 1490
Clinic Date: 23/9/2022

Dr Matthew J. Best
Cardiology
Perth Cardiovascular Institute
PO Box 342
NEDLANDS WA 6909

Dear Matthew

Patient Name: Matthew MURTAGH

UMRN: D7403080
• DOB: 2/9/1996

I caught up with Matthew via telephone today. We last reviewed him in December 2021 regarding a diagnosis of Brighton level 4/5 pericarditis with onset following his first Pfizer vaccine dose. Matthew said that his symptoms have gradually improved since the last review, although he still has some lingering symptoms. These include chest discomfort when lying flat, particularly when in bed at night and when waking in the morning, and also intermittent palpitations and exercise intolerance.

Matthew has had further review with Dr Matthew Best, Cardiologist. I understood from Matthew that a cardiac MRI was performed which showed evidence of myocardial scarring. This may mean that he also had a degree of myocarditis during his initial presentation.

Regarding re-exposure to COVID vaccines in the setting of vaccine-induced myocarditis, we would recommend that Matthew avoid all COVID-19 vaccines for now, pending development of any evidence which suggests re-exposure is safe.

I also had a discussion with Matthew about the nature of his ongoing symptoms. Given that there is no evidence of persisting cardiac inflammation, it could be that he has developed a pain syndrome, potentially with a neurological basis. I understand that he has already had a discussion with a family friend who is a doctor that has had involvement with a 'Long COVID' clinic over East; they have apparently recommended a Neurology referral, which I agree would be a reasonable next step if there are significant ongoing symptoms.

I will not organise another appointment for Matthew for now, but if there are any ways we can be of assistance in the future, please do not hesitate to contact us.

Yours sincerely

Electronically approved by

Dr Matthew Krummenacher
Consultant

cc: Matthew B. Murtagh,

Dr Russell Bock(Faxed), Whitfords Avenue Medical Group, PO Box 312, KALLAROO WA 6923

Please note our new practice details for future communication

01/03/2023

Dr James Setiawan

Whitford Avenue Medical Group
Suite 2/ 276 Dampier Avenue
KALLAROO WA 6025

Matthew Murtagh DOB: 02/09/1996

Phone: 0450947732

Re:

6 Lavinia Court, KALLAROO 6025

Dear James,

Thank you for referring Matthew. He is a 26-year-old man who I saw in the rooms today. He had a Pfizer vaccine for COVID in September 2. Subsequently, he has been diagnosed with pericarditis and myocarditis. He has been reviewed by cardiologist and immunologist for the same. He developed a number of symptoms like burning in the chest, palpitations, internal vibrations, feeling hot and decreased sleep. At some point, there was concern raised about autonomic dysfunction and hence he was referred to me. He actually improved to a point that he was back to normal. He felt motivated to restart his work, which he did about two weeks ago. Unfortunately after working for a week of doing manual labour, he had similar symptoms come that forced him to stop the work; however, the symptoms have resolved after about three days and he has been well now for almost a week. He feels alcohol is a trigger for the symptoms and he has cut back. He is also on a nicotine patch for his smoking hoping that it might help improve his symptoms.

He is otherwise well and is on no regular medications. He has done surveyor work in the past. He lives with his parents. He reports one of the aunts who vaccine-related complications as well.

On examination, his blood pressure was 134/76 mmHg with a heart rate of 84 beats per minute and regular. The visual acuity was 6/6 uncorrected. He had normal central fundus examination with no spontaneous venous pulsations. He is a right-hand-dominant person. He had normal cranial nerve examination. He had normal tone, bulk, power, reflexes, coordination and sensations in both upper and the lower limbs. The plantars were downgoing bilaterally. He had normal gait and posture. He did not report any incontinence.

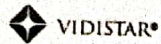
I am unable to find a neurological cause for Matthew's symptoms. For the sake of completion and reassurance, I have organised an MRI brain and cervical spine and I am happy to give him a call after that to discuss the results. I have not made any regular arrangements to see him, but he may discuss with any symptomatic management that may help him sleep better and may also help improve his symptoms. I did suggest Endepe can work well in this situation. However, I am not sure if that can affect his QTc interval adversely and hence may require cardiologist approval.

Thank you once again for referring Matthew.



Dr Darshan Ghia
Dictated but not sighted to expedite delivery

LB

**72 hour Holter monitor Report**

Patient name: MURTAGH, MATTHEW			Patient ID: 92293	
DOB: 02/09/1996	Inpt/Outpt:	Outpatient	Referred by:	James Setiawan
Age: 26Y	Location:	Joondalup		
Sex: M	Equipment:	Holter DMS 3 Lead	Technician:	Rachael Brown
	Exam.date:	20/03/2023		
			Interpreting physician:	Dr A.Brown, MDBSc (Hons), MBBChir, PhD, MRCP, FRACP
Indications / History:		Palpitations. B/g myocarditis post Pfizer vaccination.		
Procedures:		CardioScan		

Conclusions

Sinus rhythm throughout.

(Mild nocturnal sinus arrhythmia noted at times).

Monitoring commenced at 13:30 and continued for 72 hours.

Minimum Heart Rate was 34 bpm, Average Heart Rate was 65 bpm, and Maximum Heart Rate was 182 bpm.

Ventricular Ectopy (1), with 1 isolated VE.

Atrial Ectopy (6), with 6 isolated SVEs.

2 pauses lasting 2.02 and 2.06 respectively, both were noted to be due to 2nd degree AV Block (Mobitz I Wenckebach).

No diary entries/symptoms reported.

Conclusion:

Sinus rhythm throughout with no sustained arrhythmia documented.

Electronically signed by: Dr A.Brown, MDBSc (Hons), MBBChir, PhD, MRCP, FRACP
03/27/2023 8:59 PM

Patient Name: MURTAGH, MATTHEW
Patient Address: 6 LAVINIA COURT, KALLAROO 6025
D.O.B: 2/09/1996 **Gender:** M
Medicare No.: **IHI No.:**
Lab. Reference: 479722 **Provider:** myglobal
Addressee: JAMES SETIAWAN **Referred by:** JAMES SETIAWAN

Date Requested: 28/03/2023 **Date Performed:** 28/03/2023
Date Collected: 28/03/2023 **Complete:** Final
Specimen:
Subject(Test Name): HOLTER MONITORING