

This is an official medical report. If you are not the intended recipient please contact our radiology practice immediately and advise us.

QUEENSLAND X-RAY PTY LTD ABN 40 094 502 208
Cairns Private Hospital, CAIRNS, QLD, 4870
Telephone : 07 4046 7800 Facsimile : 07 4051 3028

Saturday, 6 January 2024

DR CHAUDHRY FARHAN MASUD
17 CATHERINE STREET
MALANDA QLD 4885

RE: MRS CHARMAINE SAVAGE (08/01/1972)
48 BELLAMY DRIVE
TOLGA QLD 4882

Patient ID : QXR4129012
Service Date : 05/01/2024
Dept :
UR No :
Episode ID : CPH21067114

EPID:
mxm9/loc/era

ULTRASOUND PELVIS

Indication

Follow up known fibroids. Menorrhagia. Perimenopausal.

History

Prev. surgeries	Ectopic pregnancy (R) surgical intervention.
OB History	Gravida 1. Para 0
	Ectopic 1

Assessment

LMP on 28/11/2023. Day of cycle 39. Cycle: irregular cycle. Bleeding: heavy. Contraception: none. HRT: No
HRT

Method

Transabdominal and transvaginal US. View: Average.

Uterus

Visualised. Long 95 mm x ap 85 mm x tr 67 mm. Vol 283.0 cm³

Position: anteverted

Endometrium: Slightly displaced posteriorly by fibroids. Endometrial thickness, total 6.1 mm

Cervical length 44 mm

MRS CHARMAINE SAVAGE (DOB: 08/01/1972) 1

This is an official medical report. If you are not the intended recipient please contact our radiology practice immediately and advise us.

QUEENSLAND X-RAY PTY LTD ABN 40 094 502 208

Cairns Private Hospital, CAIRNS, QLD, 4870

Telephone : 07 4046 7800 Facsimile : 07 4051 3028

Fibroid(s) 1. Size 37.9 mm x 33.4 mm x 32.8 mm. Subserosal 50%

Intramural 50%. Posterior. Lower.

2. Size 20.3 mm x 16.2 mm x 18.6 mm. Intramural 100%. Right.

Mid body.

3. Size 45.3 mm x 44.4 mm x 46.3 mm. Subserosal 50%

Intramural 50%. Fundal. Midline.

4. Size 17.7 mm x 16.6 mm x 16.1 mm. Subserosal 50%

Intramural 50%. Fundal. Midline. Posterior.

5. Size 42.0 mm x 42.0 mm x 41.0 mm. Subserosal 100%. Left.

Posterior. Lower.

Please note: today's volume measurement includes cervix

Right Ovary

Visualised. Size 19 mm x 16 mm x 16 mm. Vol 2.5 cm³

Follicle(s) Size 11.0 mm

Free movement of right ovary with applied pressure.

Left Ovary

Visualised. Size 23 mm x 18 mm x 13 mm. Vol 2.9 cm³

Follicle(s) 1. Size 11.0 mm

2. Size 8.0 mm

Free movement of left ovary with applied pressure.

Right Kidney

95mm.

Left Kidney

94mm.

Conclusion: No prior imaging is available for comparison. There is a bulky fibroid uterus as described. No endometrial lesion is identified. no concerning ovarian or adnexal lesion is detected.

Dr Morgan McMeniman

Queensland X-Ray

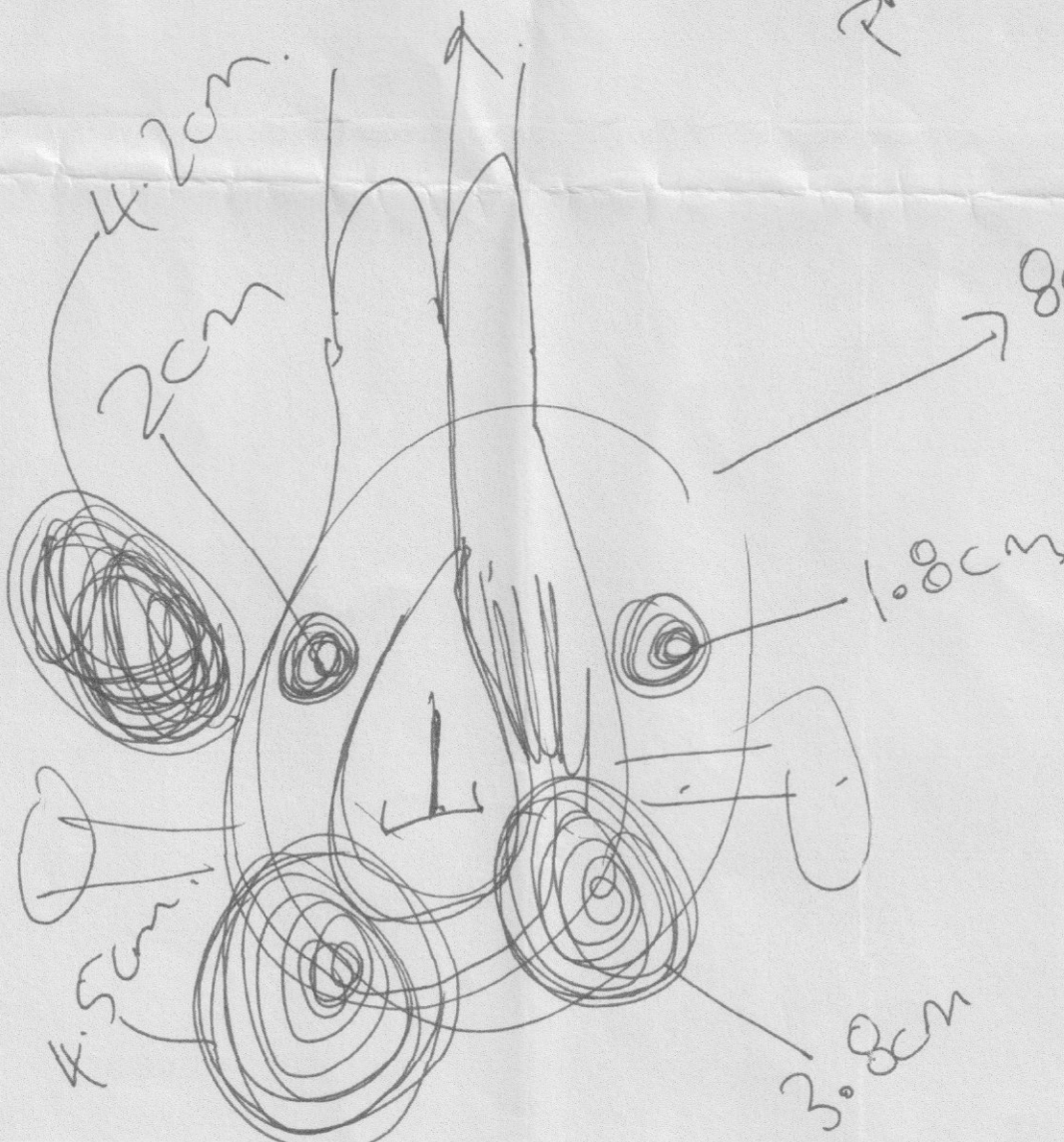
Oral $\begin{cases} \text{Pill} \\ \text{mini pill} \end{cases}$

Implants - Mirena

Supp $\begin{cases} \text{ablation} \\ + \\ \text{Mirena} \end{cases}$

hysterectomy

Fibroids $\begin{cases} \text{O.I.I. cancer} \\ \text{menstrual} \\ \text{fertility} \\ \text{pressure} \end{cases}$



$$\begin{array}{r} 7293g \\ \times 3.5 \\ \hline \end{array}$$