

Gastroscopy

29 November 2022 at 10:04 AM at St John of God - Subiaco

† 1300 427 876

(1300 GASTRO)

f (08) 9382 9427

w www.gihealthclinic.net.au

St John of God Hospital

Suite H202

12 Salvado Rd

Subiaco WA 6008

Tracy **HARRINGTON**

DOB: 2/11/1965, URN:

Procedure details:

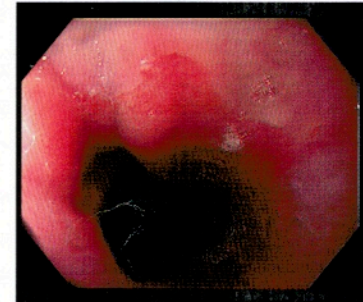The patient was referred by Dr Neels Myburgh for the endoscopic assessment of mild dysphagia. Sedation was administered by Dr Charlotte Jorgensen. The endoscope was inserted to the second part of duodenum. The preparation and views were excellent.

Findings :

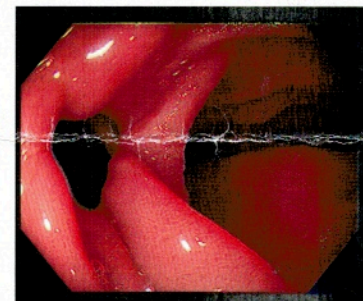
Oesophagus: Normal. No evidence for inflammation, reflux oesophagitis, ulceration, Barrett's mucosa or varices. The scj and goj were at 40 cm.

Stomach: Occasional small fundic gland type gastric polyps in the body of the stomach less than 5mm in diameter.

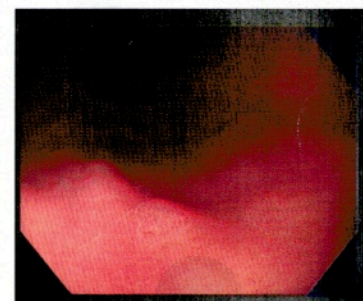
Duodenum: Small duodenal diverticulum noted in the second part of the duodenum.



oesophagus | Normal



duodenum (D2) |
diverticulum



stomach | polyp

Conclusions :

Diminutive gastric polyps of no clinical relevance. Small duodenal diverticulum of limited clinical relevance. A repeat procedure is not indicated.

Instructions:

- * Please see Dr Neels Myburgh within the next 1-2 weeks for followup of this result.
- * The following sample(s) were taken: biopsy. Results will be sent to your doctor. St John of God Pathology [results phone 92132173].
- * Please read the discharge instruction sheet. See a doctor immediately if you pass large amounts of blood or black tar-like bowel actions, or have severe abdominal pain that lasts more than 30 minutes.

Copies to : Medical notes | patient copy | Pathology (if requested) | Dr Neels Myburgh, Modern Medical Clinics, 66 - 70 Mahogany Drive, HALLS HEAD, WA 6210

Dr Colin Sherrington

B Med Sci, MB BS(hons), FRACP, PhD

Dr Donald Ormonde
MBBS FRACP PhD
Gastroenterologist

Dr Charlie Viiala
MBBS FRACP
Gastroenterologist

Dr Colin Sherrington
MBBS FRACP PhD
Gastroenterologist
Item Number 30473

P R O C E D U R E R E P O R T