

IVF Australia
Dr Rabia Shaikh
L2, 20-22 Mons Road
Westmead 2145

Dear Dr Shaikh

Patient: Narmeen Sumar Patient ID (Genie): 27894
Date of birth: 31/08/1990 (35 years) OLD Westmead ID:
Exam: Exam date: 9/09/2025
Cervical Assessment

Indication Cervical length assessment
Post cerclage

History OB History Gravida 1. Para 0

**Fetal Growth
Overview**

Exam date	GA	BPD (mm)	HC (mm)	AC (mm)	FL (mm)	HL (mm)	EFW (g)
26/08/2025	12w 4d	22.7 58%	81.8 69%				

Pregnancy Singleton pregnancy. Number of fetuses: 1

Dating

	Date	Details	Gest. age	EDD
LMP	1/06/2025	Cycle: regular cycle	14 w + 2 d	8/03/2026
Conception		Conception: spontaneous		
External assessment			14 w + 3 d	7/03/2026
Agreed dating	based on the external assessment		14 w + 3 d	7/03/2026

Fetal Biometry

CRL	89.2 mm
-----	---------

**General
Evaluation**

Cardiac activity present. FHR 161 bpm. **Fetal movements:** visualised
Placenta: Placental site: posterior
Amniotic fluid: normal amount

**Maternal
Structures**

Cervix Approach - Transvaginal: Cervical length 27.2 mm
stitch seen about 15 mm from external os

Impression

Viable singleton pregnancy.
The cervix is closed.
Transvaginal cervical length 29 mm.
A cerclage was difficult to identify on the scan today.
There is no evidence of dynamic change, funneling or sludge.

Westmead

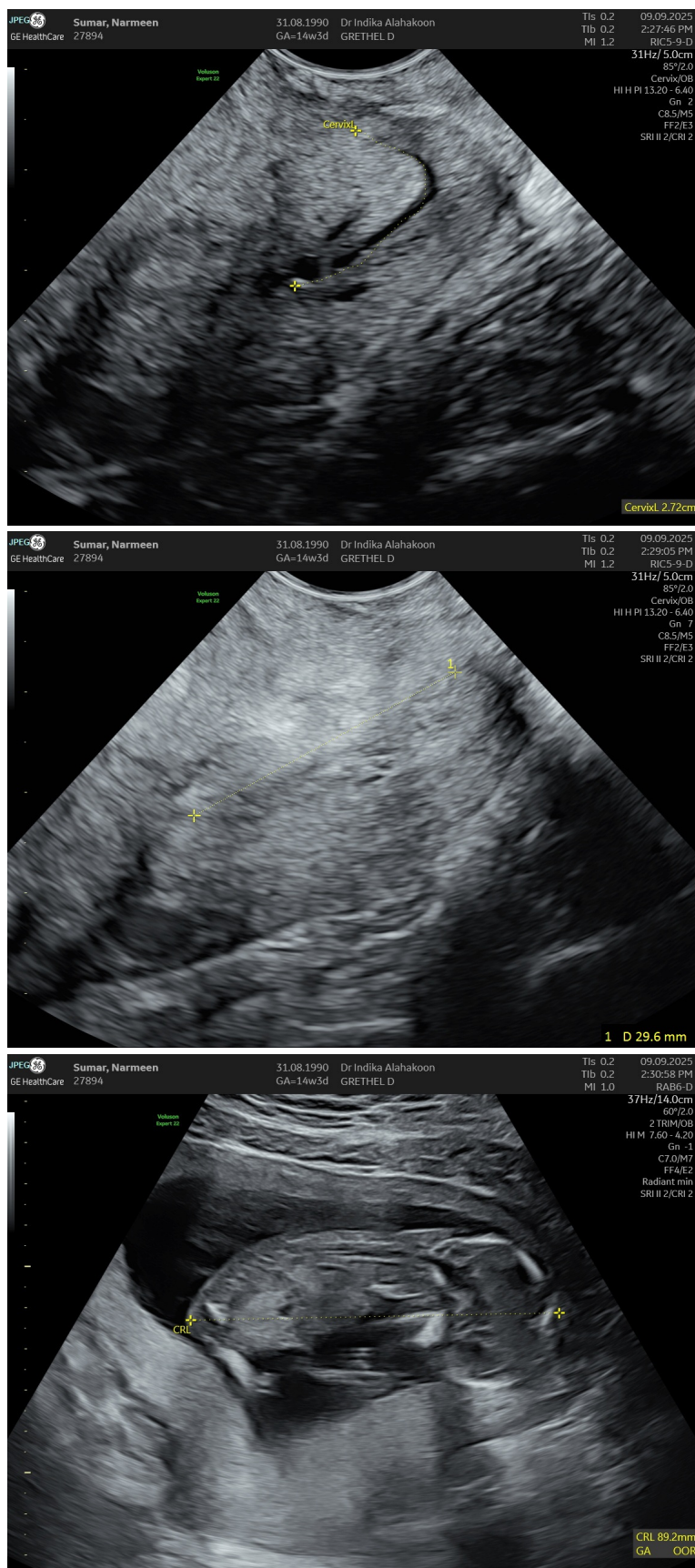
Suite 1.02, Innovation Quarter, 160 Hawkesbury Rd, Westmead NSW 2145
Mail PO Box 545 Westmead NSW 2145
T 02 9687 5555 | F 02 9687 5722 | E info@cfwu.com.au | W cfwu.com.au

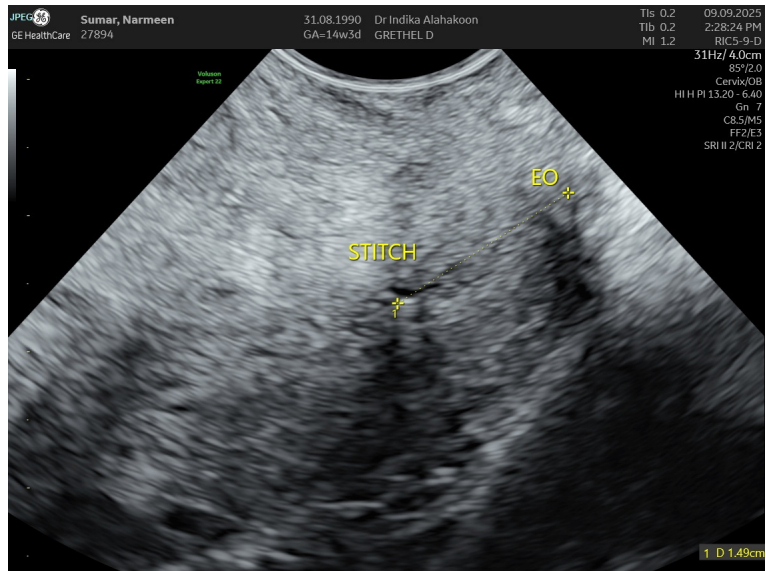
Bella Vista

Suite 108, Specialist Medical Centre, Norwest Private Hospital
9 Norbrik Dr, Bella Vista NSW 2153
T 02 9836 3558 | F 02 9836 3872 | E info@indika-alahakoon.com.au

Follow-up

Further review of the cervix recommended in 2 weeks.





Kind regards

Kind Regards,

A/Prof. Indika Alahakoon
Maternal Fetal Medicine Specialist

D GRETHEL