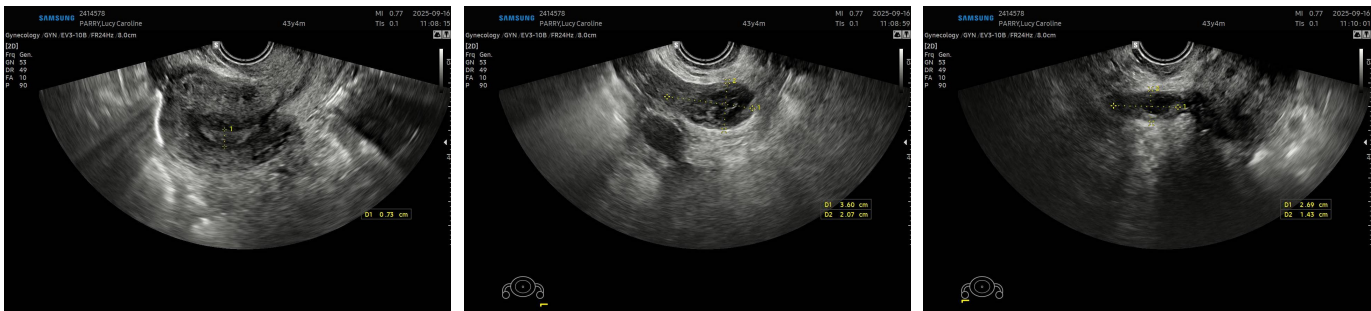


Name 姓名:	PARRY Lucy Caroline			Age 年龄:	43岁
DOB 出生日期:	1982/4/20	MRN 病历号:	2414578	Sex 性别:	女
Date of Exam 检查时间:	2025/9/16 11:03:32		AccessionNumber 检查号:	R02324807-10-US	
Exam Item 检查项目:	Ultrasound , pelvis , transvaginal 经阴道盆腔超声检查				

Report 检查报告:



Description 超声描述:

Transvaginal ultrasound examination:

The uterus is in an anterior position, approximately 4.8 x 4.5 x 4.5 cm in size. The surface of the uterus is smooth, and the myometrium shows heterogeneous echoes. A hypoechoic nodule is visible on the anterior wall, approximately 0.7 x 0.5 cm in size. The endometrium is about 0.73 cm thick and is centrally located.

The right ovary measures 2.7 x 1.4 cm, with three follicular echoes visible, the largest being 0.9 x 0.6 cm. The left ovary measures 3.6 x 2.1 cm, with one follicular echo visible, approximately 0.5 x 0.3 cm in size. Additionally, a cystic echo is seen with poor acoustic transmission, approximately 2.7 x 1.7 cm in size. CDFI: A ring-shaped blood flow signal is visible around it.

No obvious abnormal masses are seen in the bilateral adnexal regions.

No fluid is seen in the uterorectal pouch.

Impression 超声提示:

Uterine fibroids
Cystic echo in the left ovary (physiological)
子宫肌瘤
左侧卵巢囊性回声 (生理性)

Reported Time 报告时间: 2025-09-16 11:21:46 Reported by 报告医师: 崔红丽 Authorised by 审核医生: 崔红丽

告知: 超声检查受诸多因素影响, 如患者自身因素 (气体干扰、准备欠佳、病变位置特殊、疾病所处不同阶段等)、设备因素 (仪器型号及性能不同、其图像质量有差异)、检查者因素 (声结论依据国内外公认的影像特征, 对图像判读不同检查者之间可能存在差异) 等。此报告是影像检查结果, 请以病理诊断或临床最后诊断为准, 与本检查相关医疗活动应充分了解上述因与临床医生沟通。